



PRESENTING CLINICAL SIGNS

DATE History: Coughing recently. No murmur. Radiographs showed enlarged cardiac silhouette, variation in tracheal diameter, and a mild bronchial pattern. Some improvement with hydrocodone.

12/16/21

ECHOCARDIOGRAPHIC FINDINGS

PERFORMED BY: 2D, M-mode, and Doppler study.

Dr. Meredith Swart Left atrial size is normal. The mitral valve appears normal, though trace mitral regurgitation is present. Left ventricular dimensions are normal. Left ventricular systolic function is hyperdynamic. The aorta and aortic are normal. Right atrial and right ventricular dimensions are normal. The tricuspid valve is normal. The pulmonary artery and pulmonic valve are normal. No heartworms are visualized. No pericardial effusion or cardiac masses are seen.

INTERPRETED BY

Keith Blass, DVM,
MS, DACVIM
(Cardiology)

LA - 34.1 mm
LVIDd - 29.8 mm
LVIDs - 15.5 mm
FS - 48%
RA - 26.3 mm
LVOT - 1.34 m/s
RVOT - 1.43 m/s

PATIENT

Daisy Kistler

SPECIES

Canine

ASSESSMENT/RECOMMENDATIONS

Normal echocardiogram

This examination demonstrates no evidence of structural heart disease, as trace mitral regurgitation can be considered a normal physiologic variant. As such, there does not appear to be a cardiac contribution to Daisy's cough.

BREED

Cocker Spaniel

No therapy is recommended based on this exam.

SEX

A recheck echocardiogram is recommended new physical exam and/or clinical abnormalities compatible with cardiac dysfunction develop.

FS

AGE

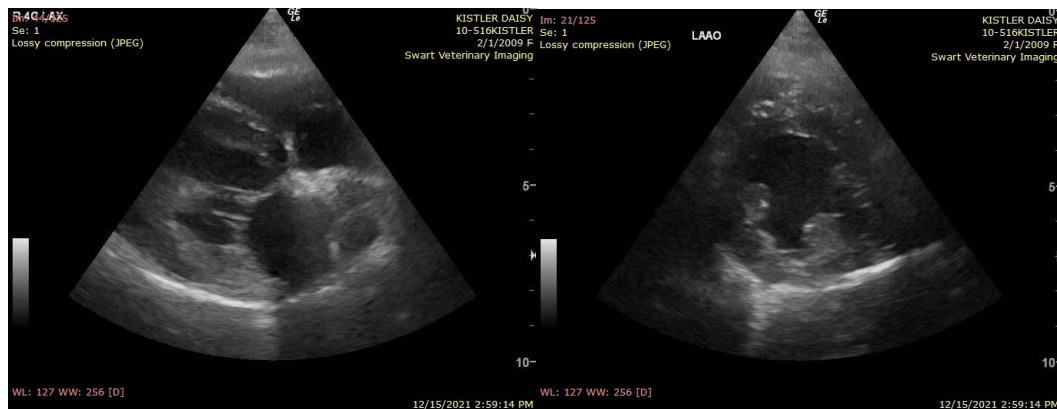
12 y

WEIGHT

40 lb

HOSPITAL NAME

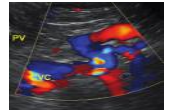
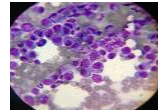
Swart Veterinary
Imaging



The information and recommendations provided are based on the images presented by the referring veterinarian. No evaluation can be communicated regarding pathology that was not visible in the image/video clips provided.

REFERRING VET

Dr. Swart



DATE

Thank you for this referral. If the clinical or image interpretation does not parallel your findings or if I can be of any further assistance please contact me.

12/16/21

PERFORMED BY:

Keith Blass, DVM, MS, DACVIM (Cardiology)
KeithBlass@gmail.com
631-804-5754

Dr. Meredith Swart

INTERPRETED BY

Keith Blass, DVM,
MS, DACVIM
(Cardiology)

PATIENT

Daisy Kistler

SPECIES

Canine

BREED

Cocker Spaniel

SEX

FS

AGE

12 y

WEIGHT

40 lb

HOSPITAL NAME

Swart Veterinary
Imaging

REFERRING VET

Dr. Swart